

DOI 10.24425/pjvs.2019.127092

Original article

The effect of activated platelet-rich plasma (PRP) on tricalcium hydroxyapatite phosphate healing in experimental, partial defects of long bone shafts in animal models

S. Skwarcz, I. Bryzek¹, A. Gregosiewicz², E. Warda, K. Gawęda,
M. Tarczyńska, J. Skwarcz³, R. Nadulski⁴, A. Starek⁵, J. Sanford⁶

Department of Orthopaedics and Traumatology, II Faculty of Medicine with English Language Division, Independent Public Teaching Hospital No 4 in Lublin, Jaczewskiego 8, 20-954, Lublin, Poland

¹ Veterinary Clinic – Bryzek and Partners, Lublin

² Department of Paediatric Orthopaedics, Medical University of Lublin

³ Department of Technology Fundamentals, Subdepartment of Modelling and Information Systems, University of Life Sciences, Lublin

⁴ Department of Food Engineering and Machinery, University of Life Sciences, Lublin

⁵ Department of Biological Bases of Food and Feed Technologies, University of Life Sciences, Lublin

⁶ Vetregen, Laboratory and Stem Cell Bank, Warsaw

Abstract

The purpose of the study was to assess the effect of autologous activated platelet-rich plasma on healing of a bone substitute - tricalcium phosphate hydroxyapatite in experimental long bone defects using an animal model.

The experiment involved an animal model of femoral defect. 24 Termond white rabbits were used in the study. We evaluated the effect of autologous platelet-rich plasma on tricalcium phosphate using classical radiology, micro-CT studies, strength tests and histological evaluation.

Radiological and histological assessment did not show a beneficial effect of PRP together with a bone substitute in comparison to filling the defects only with bone replacement material. The only benefit of adding platelet-rich plasma to a bone substitute was shown in microCT imaging.

Autologous, activated platelet-rich plasma combined with hydroxyapatite tricalcium phosphate has a positive effect on the remodeling of the newly formed bone tissue, increasing its density.

Key words: platelet-rich plasma, hydroxyapatite tricalcium phosphate, bone regeneration, bone defects, rabbit model

Introduction

Bone tissue has an ability to regenerate and remodel throughout human life. Under physiological conditions, an animal skeleton remains in a state of dynamic balance between constant, opposing processes of bone resorption and bone formation. Due to such metabolic activity, there is a balance between the content of calcium ions and phosphates in bone tissue and body fluids (bone turnover). It is these regulatory mechanisms that provide an opportunity to repair bone fracture. In case of an adult, within a year, approximately 10% of bones is replaced (Sawicki 2008). Within certain limits, if there is a need of bone repair, these properties allow to reproduce the tissue continuity and its subsequent reconstruction, the so-called remodeling, in order to adjust its structure to the local conditions. According to Delpech's and Wolff's law, remodeling takes place as a result of mechanical forces acting on the skeleton (Piątkowski and Kotwicki 2004).

The bone mineral substance has osteoconductive properties, which means that it can act as a micro-skeleton for the cells that make up bone tissue. A bone also has osteoinductive properties, namely, it stimulates undifferentiated mesenchymal cells to differentiate towards osteoblasts. It happens with participation of local regulators of bone tissue remodeling, including prostaglandins, protein growth factors and cytokines.

Nevertheless, in clinical practice, there are situations where physiological possibilities of bone tissue repair are exhausted. There are bone defects formed which, without surgical intervention, will not self-repair or their regeneration takes a very long time. Formation of bone defects may be a consequence of post-traumatic changes, abnormal healing of fractures with formation of pseudoarthrosis, post-inflammatory changes as well as bone tumors and tumor-like lesions. In such situations, veterinary and medical orthopedics as well as surgical dentistry dealing with treatment of bone tissue lesions are faced with the necessity to repair bone defects in order to restore the continuity of tissue and to regain fitness. Defect repair can be done in many ways, for example, using auto or allogeneic grafts or an industrially produced bone substitute. The above methods are limited by the size of the defect, the bigger the defect is, the more difficult and slower it is for the preparation to heal in. The clinical experience shows that while autogenic grafts usually heal well in the area of the defect, in case of allogeneic grafts and bone substitutes, this process is often unpredictable. This fact triggered attempts to search for methods accelerating osseointegration of bone substitutes.

Bone substitutes may be of bone origin (e.g. a demineralised bone matrix) or they are synthesized and mor-

photically shaped, mainly on the basis of calcium phosphate (hydroxyapatite) [HA], calcium triphosphate [TCP] and calcium sulphate. They have good osteoconductive properties, ensuring a certain mechanical resistance in the defect area once they are applied. However, they consist of neither osteogenic cells nor signal substances that are necessary to initiate and ensure a correct course of bone tissue regeneration.

According to the Lynch triad, correct healing of bone tissue is possible under three conditions (Williams et al. 2005). Firstly, there ought to be an auto or allogenic carrier (a bone graft, a bone substitute). Secondly, signaling molecules are necessary, e.g. cytokines, hormones, morphogenetic proteins (BMPs). Thirdly, it is essential that there are stem cells that can be affected by the said signaling molecules and which can differentiate into osteogenic cells on the bone graft or substitute.

Platelets, among others, can be a source of the said signaling molecules. Apart from secretion of factors involved in coagulation and fibrinolysis, proteolytic enzymes and antibacterial proteins, thrombocytes are a source of cytokines taking part in the process of bone tissue regeneration, for instance, such as: platelet derived growth factor – PDGF, transforming growth factor – TGF- β , and BMP, as well as vascular endothelial growth factor (VEGF) (Sulek 2011).

Platelet-rich plasma is used both in veterinary and human medicine for a wide range of indications. In the clinical practice, it is used in a recognized therapeutic procedures in treatment of soft tissue pathology, mainly entesopathy and tendinopathy (Hsu et al. 2013). However, it can be used alone or as a type of adjuvant therapy also in treatment of pathologies related to bone tissue, cartilage, in soft tissue injuries, aesthetic medicine and dentistry. Nevertheless, in many indications its effectiveness is sometimes questioned (Hsu et al. 2013). Relatively more doubts arouse over its effectiveness in treatment of bone damage (Skwarcz and Bryzek 2015).

The purpose of our study is to assess the effect of autologous activated platelet-rich plasma on healing of a bone substitute - tricalcium phosphate (80%) hydroxyapatite (20%) in experimental, unicortical long bone defects using an animal model.

Materials and Methods

The experiment involved an animal model of unicortical femoral defect. 24 Termond white rabbits were used in the study. They were 15-16 weeks old males. Before the experiment started, the consent of the First Lublin Local Ethical Committee for Experiments on Animals required by legal regulations had been obtained (Resolution No. 6/2013 of 18.01.2013). The animals were subject to a routine two-week quaran-

tine during which there were no signs of diseases disclosed that could affect the course of the experiment. Before the surgical procedures, the rabbits were premedicated (Xylazine - 20 mg/ml - dose: 5 mg per kg bodyweight) and then they underwent general anesthesia by intramuscular administration of Diazepam and Ketamine, at doses of 1.5 mg/kg, and 30 mg/kg, respectively. The animals were randomly divided into two groups A and B not statistically different in terms of average weight and age (group A: 2.98 ± 0.07 , group B: 3.01 ± 0.17). Immediately before the surgical procedures, the blood was collected from each animal: 2 ml of whole blood in order to determine platelet count and 4 ml of whole blood required to obtain platelet-rich plasma. In both groups, in each of the femurs, in the middle of the determined length, a unicortical, cylindrical bone defect of 4 mm in diameter was generated. In group A, the left-femur defects (marked in the study with the letters "AL") were left untreated, whereas the area of the right bone defect (marked in the study with letters "AP" - the test group) was filled with 100 mg of tricalcium phosphate (80%) hydroxyapatite (20%). In group B, the left femur defects (marked in the study with letters "BL") were left untreated, whereas the area of the right bone defect (marked in the study as "BP" - the test group) was filled with 100 mg of tricalcium phosphate (80%) hydroxyapatite (20%), which was saturated with 0.7 ml of autologous, activated platelet-rich plasma (PRP). In group B, PRP was separated during preparation of the animal for the surgery. After the blood centrifugation and separation of the platelet-rich plasma (PRP) (0.6 ml each time), 0.1 ml of thrombin was added. It was obtained from one of the animals, from which 4 ml of the whole blood was additionally taken to a sample tube containing a clotting activator, from which, after the centrifugation, the thrombin essential for the activation was obtained. Then, 0.1 ml of 10% calcium chloride (CaCl_2) was added. This way, 0.8 ml of activated PRP was obtained, from which 0.1 ml was taken each time. Next, the platelets count in 1 ml of the preparation was determined, compared to the amount of thrombocytes in 1 ml of the whole blood and in this way it was found that the concentration of platelets obtained in the preparation was 4.46 ± 0.24 times higher than in the whole blood of the animal and it did not differ significantly in terms of statistics between the subjects.

Immediately after the surgery, and then every 7 days, a control X-ray imaging was performed in two orthogonal projections in order to monitor the healing process.

On the 56th day, after the surgery and premedication, the animals were sacrificed with intravenous injection of Morbital (133.3 mg/ml Pentobarbital sodium, 26.7 mg/ml Pentobarbital) at the dose of 1ml per kg

of body weight. Then the femoral bone preparation was collected.

Two orthogonal dimensions (X,Y) were determined within the defect area in order to establish the difference between the left and right femur dimensions within the defect ($\Delta\text{-X}[\text{mm}]$, $\Delta\text{-Y}[\text{mm}]$). Then, using the Skyscan 1174, microCT of the examined femurs was performed. Within the femurs, there was determined a Region of Interest (ROI) in shape of a cuboid with a square base, side length of 4 mm and variable height, including the defect zone in such a way that the tested area covered the drilling zone and the area of the marrow cavity, but without the opposite cortical layer. The computer analysis of the examined area allowed to divide the examined zones in terms of tissue density (Jui-Ting et al. 2014) on the basis of the grey scale (in absolute values ranging from 15 to 225). In the study, the high density areas were considered those that ranged from 75 to 225 in the grey scale. In the examined area, following parameters were determined: the total tissue volume within the ROI (V_b [mm^3]), the volume of the high density tissue fraction within the ROI (V_{b_1} [mm^3]), the volume of the low density tissue fraction within the ROI (V_{b_2} [mm^3]) calculated according to the equation: $V_{b_2} [\text{mm}^3] = V_b - V_{b_1}$. Then, the average values were determined, separately for the left and right bones in each group, the difference in the values obtained was calculated in a given group between the left and right bone ($\Delta\text{-}V_b$ [mm^3], $\Delta\text{-}V_{b_1}$ [mm^3], $\Delta\text{-}V_{b_2}$ [mm^3]) and the statistical significance of the difference between group A and B was determined.

In order to assess the changes in the bone tissue strength in the area of the defect, the maximum force test [F max] and work [W] necessary to break the bone at the site of the generated defect were used.

The last component of the assessment was a histopathological examination of the tissue samples taken from the defect area and a qualitative verification in terms of size differences of bone formation in individual groups. For this purpose the preparations obtained were placed for a period of 3 days in a solution of 7% nitric acid for decalcification. Next, tissue samples were taken from the zone of healed defects. The collected preparations were rinsed for 30 minutes in a sulphate solution. The material was transferred to 73% ethanol for a period of two hours, followed by 96% ethanol, in which they were immersed for a period of twelve hours. In the subsequent stages, preparations were kept for two hours in acetone and then for two hours in xylene. Then, the tissue sections prepared in this way were embedded in paraffin for twelve hours at 56 °C, and after that paraffin blocks were formed and cut using microtome to 0.3 micron sections. After that samples were stained

Table 1. Mean value and standard deviation of difference in X and Y dimensions between the left (group AL, BL) and right bone (group AP and BP) within the defect.

	Delta-X (mm)	Delta-Y (mm)
Group A	3.00 ± 0.63	1.54 ± 1.25
Group B	1.17 ± 0.74 p < 0.001	0.33 ± 0.34 p < 0.05

Table 2. Mean values and standard deviation of difference in volume between the left and right bone: total tissue volume (Delta-Vb), tissue fraction of high density (Delta-Vb₁) and tissue fraction of low density (Delta-Vb₂) within the ROI

	Delta-Vb (mm ³)	Delta-Vb ₁ (mm ³)	Delta-Vb ₂ (mm ³)
Group A	48.46 ± 18.04	-5.16 ± 8.60	44.92 ± 34.00
Group B	32.32 ± 15.02	10.60 ± 14.63 p < 0.05	21.72 ± 9.53

Table 3. Mean values and standard deviation of maximum breaking force [F max] and work (W) within the right and left femur and mean differences between the right and left femur in particular groups.

	F max (N) L	F max (N) P	Delta – F max (N)	Work W (J) L	Work W (J) P	Delta – W (J)
Group A	311.7 ± 72.6	342.9 ± 64.0 p < 0.01	31.2 ± 26.5	0.31 ± 0.08	0.42 ± 0.16 p < 0.05	0.11 ± 0.16
Group B	252.6 ± 50.8	307.4 ± 66.5 p < 0.05	54.8 ± 65.9	0.23 ± 0.08	0.38 ± 0.13 p < 0.01	0.15 ± 0.13

with hematoxylin and eosin (H+E) and then evaluated using the Olympus BX41 microscope.

Results

During the surgery of one of the animals from group A, there was a multi-fracture of the left femoral shaft. For humanitarian reasons, the animal was euthanized. In case of the remaining animals, the assessment of the X-ray images obtained immediately after the surgery proved lack of complications and the correct course of the surgical procedure. On the 10th day after the surgery, one of the animals from group B died without any previous disease symptoms.

The analysis of the X-ray images in group A on the 7th day showed the occurrence of fractures in both femurs in two subjects. Because of that, the animals were euthanized. In the remaining subjects, there was observed a gradual “blending” of the structures of the bone replacement material in the right bone defects (group AP) accompanied by a gradual intensification of the periosteal reaction in form of the clear bone augmentation within the cortex layer in the injury zone. Within the left femur defects (group AL), there was observed a gradual, radiological increase in the density of the tissue filling the defect accompanied by a slight periosteal reaction.

In group B, on the 7th day after the surgery, the X-ray images revealed fractures of both femurs in one subject - the animal was euthanized. Within the right femurs (group BP) there was observed an increase in the fairly strong periosteal reaction and a gradual “blending” of the bone substitute structure. The left femur defects (group BL) were filled with the tissue of increasing density.

Due to the occurrence of the above mentioned complications, the further analysis involved 9 subjects from group A and 10 from group B.

The analysis of the difference between X (Delta-X) and Y (Delta-Y) dimensions demonstrated a statistically significant smaller increase in both dimensions within the group where tricalcium hydroxyapatite phosphate together with PRP were used, compared to the group where only a bone substitute was used (Table 1).

The microCT studies observed both in the bones filled with only a substitute (AP) and in those filled with a bone substitute together with PRP (BP) in the ROI zone, the increase in the mean total volume of the tissue within the defects. However, there was no statistically significant difference in the average increases in the total tissue volume between the left and right bone and between group A and B (Delta-Vb [mm³]). Examining the tissue in terms of both qualitative and quantitative factors, there were differences between the fraction volume of the tissue of high and low density within the

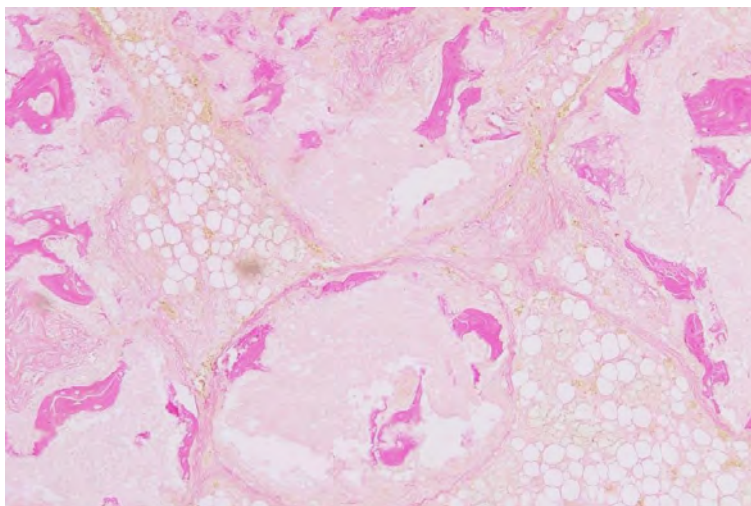


Fig. 1. Right femur preparation (H-E) of the rabbit from group A. x200

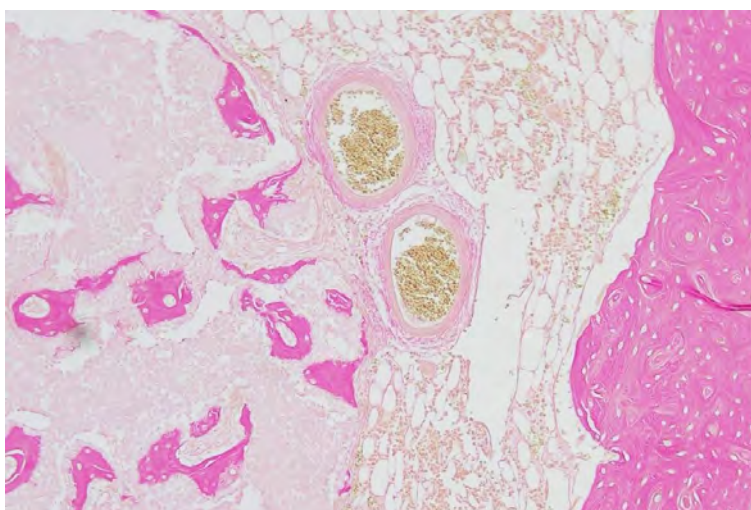


Fig. 2. Right femur preparation (H-E) of the rabbit from group B. x200

ROI between the right and left bone and between group A and B ($\Delta\text{-Vb}_1$ [mm^3], $\Delta\text{-Vb}_2$ [mm^3]). There was demonstrated a statistically significant increase in the mean volume of the high density tissue ($\Delta\text{-Vb}_1$ [mm^3]) in group B with a bone substitute with PRP compared to group A where only a bone substitute was used, as well as a statistically insignificant decrease in the mean volume of the low density tissue ($\Delta\text{-Vb}_2$ [mm^3]) (Table 2).

In the three-point test in groups A and B, when the right and left bones were compared, a statistically significant increase in both the maximum breaking force [F max] as well as work [W] was demonstrated within the bones where the defects were filled with a bone substitute (group AP) or a bone substitute and PRP (group BP) compared to the opposite side where the defects were left without filling (AL, BL). Nevertheless, the comparison of the average differences between the right and left bone in the particular group did not

differ significantly from a statistical point of view between groups A and B with respect to both parameters examined (Table 3).

In the qualitative histopathological assessment of both groups (AP, BP) examined, no significant differences were observed in the microscopic image. In both groups examined, there were visible amorphous particles of bone substitute with zones of bone formation within the preparation. There were also observed signs of intensified periosteal reaction with exocrine bone formation. There were not observed any areas of inflammation or necrosis within the assessed zones (Figs. 1 and 2). The defect zones in the left femurs (AL, BL) were almost completely filled with the osteoid tissue. No periosteal reaction was noted.

Discussion

The combined use of platelet-rich plasma (PRP) and bone substitutes is presently of great interest to many researchers. An undeniable drawback of using platelet-rich plasma is the presence of numerous variables both in the preparation production, methods of its activation as well as ways of administration. In the analyzed literature, there is also a very large diversity in the research models applied and methods for assessing the method effectiveness. In many papers, the authors emphasize the availability of studies of only low quality and a necessity to standardize methods of production and assessment of effectiveness of platelet-derived preparations (Roffi et al. 2013, Grageda 2014).

In his article, Hsu et al. summarized the effectiveness of using platelet-derived preparations for particular indications on the grounds of evidence-based medicine (Hsu et al. 2013). In that paper it was recommended to use PRP in a number of orthopedic indications, particularly those related to soft tissues, for example, in enthesopathies within the distal humerus, in graft maturation in reconstructions of anterior cruciate ligaments. In case of treatment of cartilage pathology, it was indicated that it was necessary to carry out further studies. In bone tissue pathologies, it was assessed that there were no studies confirming the effectiveness of PRP in their treatment. There are also reports where the authors claim that using PRP in combination with allografts due to the release of about 30 cytokines, may - after a period of time - cause a reaction leading to a graft destruction (Bielecki et al. 2012).

Since it is difficult to objectively assess the effectiveness of PRP in bone tissue pathologies, the vast majority of studies is based on animal models. In the analyzed experiments which investigated the effect of platelet-rich plasma on a bone substitute, various bone substitute materials were used. The choice of a bone substitute itself can affect the possible benefit of adding PRP to it. In spite of the fact that hydroxyapatite (HA) and calcium metaphosphate (CMP) alone are not able to activate platelets, collagen-grafted HA and collagen-grafted CMP can activate platelets and affect growth factors.

Our experiment used tricalcium phosphate (80%) hydroxyapatite (20%) (HA/ β -TCP) which is widely used in everyday clinical practice in our centre as a supplement to bone placement in benign tumors, post-traumatic lesions and in bone tissue deficits in severe degenerative lesions or revision surgical procedures of joint replacements.

Our experiment used a model of unicortical, cylindrical rabbit femoral shaft defect, which did not meet the criterion of Critical Size Defect (CSD), since in the

control group it was healed exclusively due to the repair abilities of the animal tested. After the end of the experiment, 6 weeks after the surgical procedures, we used five different methods of assessment of the PRP effect on bone substitute healing. Both the radiological and histological assessment did not show a beneficial effect of PRP together with a bone substitute on bone defect healing in comparison to filling the defects only with bone replacement material. The endurance test demonstrated an increase in both tested parameters: maximum breaking force [F max] and work [W] within the bones in which the defects were filled with a substitute, which proves that the bone replacement material itself improved bone resistance to fractures at the site of the defect. Nevertheless, the experiment did not show any increase in these parameters when platelet-rich plasma was added to a bone substitute. However, there was noted a smaller external bone dimensions in the group where the defect was filled with the bone replacement material together with PRP. The only benefit of adding platelet-rich plasma to a bone substitute was shown in microCT imaging, where a statistically significant increase in the tissue fraction of high density was observed when a bone substitute was used together with PRP in comparison to a situation when the defects were filled only with bone replacement material. This observation may prove a possible effect of PRP on the remodeling of the newly formed bone tissue. Similar observations about a beneficial effect of PRP on the remodeling of the newly formed bone tissue by increasing its density are presented in a number of papers (Velich et al. 2004, Kaushick et al. 2011, Oryan et al. 2012).

In the available literature, however, we have found a few papers that analyzed the effect of PRP on healing of the two-phase bone replacement material we investigated, that is, tricalcium phosphate (80%) hydroxyapatite (20%) (HA/ β -TCP). In the first of them, using a rabbit material, there was investigated an effect of PRP added to a bone substitute on healing of the experimental skull bone defect meeting the CSD criterion. The histological and histomorphometric assessment made in the 2nd, 4th and 6th week proved no beneficial effect of adding PRP to bone replacement material (Faratzis et al. 2012).

Two other papers concern the same material and they were written by the same authors. The studies conducted on rats assessed the effect of PRP added to HA/ β -TCP on healing of skull bone defect that did not meet the CSD criterion. The histological and histomorphometric assessment as well as the microCT imaging demonstrated no effect of PRP on the early stage (4 weeks) of defect healing when it was added to the bone replacement material tested (Plachokova et al.

2006, Plachokova et al. 2007). In turn, El Backly et al. examined in their paper an effect of hydroxyapatite tricalcium phosphate (HA/ β -TCP) on healing of bone defects in the skull of rabbits. They observed that adding PRP to osteoconductive material as a source of growth factors stimulates bone formation by activation of stem cells and it improves cellularity within the defects. Their observations were based on the histological and microCT examinations which were conducted 8 and 16 weeks after the surgical procedures (El Backly et al. 2013). There is also a report of a beneficial effect of platelet-rich plasma added to HA/ β -TCP used in treatment of periodontal cysts in humans (Kaushick et al. 2011).

In the analyzed papers which assessed the effect of platelet-rich plasma on other bone substitutes, there is also a large discrepancy in the results obtained. There is a lot of publications proving a beneficial effect of PRP on healing of, for instance: hydroxyapatite, calcium triphosphate (β -TCP) or calcium phosphate (Suba et al. 2004, Okuda et al. 2005, Jungbluth et al. 2010, Kim et al. 2010, Kamoda et al. 2012, Oryan et al. 2012). In contrast to the above publications, there is also a lot of reports about no beneficial effect of PRP on bone substitute healing, for example, calcium triphosphate (β -TCP), bioactive glass of calcium phosphate (Tamura et al. 2007, Rabillard et al. 2009, Özdemir and Okte 2012, Özdemir et al. 2012, Roffi et al. 2013).

Thus, the observations of Malhort et al. seem to be correct that a lot of variables, including the technology of platelet-rich plasma production itself, may have a possible beneficial effect on bone substitute healing (Malhotra et al. 2013).

Conclusions

Analyzing the results of the microCT imaging during the study period, it can be concluded that autologous, activated platelet-rich plasma (PRP) combined with hydroxyapatite tricalcium phosphate has a positive effect on the remodeling of the newly formed bone tissue, increasing its density. However, there was demonstrated no beneficial effect of adding PRP to a bone substitute on the biomechanical properties or the radiological and histological image of the preparations tested. The wide discrepancy in the results obtained by different authors investigating the same bone substitute substances seems to be caused the lack of universal, standardized research methods, both in terms of the selection of the experimental model, the method and type of the platelet-rich plasma (PRP) preparation applied, as well as the duration of the observation.

Platelet-rich plasma is undoubtedly a source of additional growth factors in the area of its application and it can be successfully used in numerous indications, also in the treatment of bone tissue pathologies. Nevertheless, it seems that the effectiveness of its application should be assessed in a particular clinical situation, under strictly defined conditions, since a lot of variables can determine effectiveness of this method.

References

- Bielecki T, Cieslik-Bielecka A, Zelawski M, Mikusek W (2012) A side-effect induced by the combination of a demineralized freeze-dried bone allograft and leucocyte and platelet-rich plasma during treatment for large bone cysts: a 4-year follow-up clinical study. *Transfus Apher Sci* 47: 133-138.
- El Backly RM, Zaky SH, Canciani B, Saad MM, Eweida AM, Brun F, Tromba G, Komlev VS, Mastrogiacomo M, Marei MK, Cancedda R (2013) Platelet rich plasma enhances osteoconductive properties of a hydroxyapatite- β -tricalcium phosphate scaffold (Skelite) for late healing of critical size rabbit calvarial defects. *J Craniomaxillofac Surg* 42: 70-79.
- Faratzis G, Leventis M, Chrysomali E, Khaldi L, Eleftheriadis A, Eleftheriadis I, Dontas I (2012) Effect of autologous platelet-rich plasma in combination with a biphasic synthetic graft material on bone healing in critical-size cranial defects. *J Craniofac Surg* 23: 1318-1323.
- Grageda E (2014) Platelet-rich plasma and bone graft materials: a review and a standardized research protocol. *Implant Dent* 13: 301-309.
- Hsu JT, Chen YJ, Ho JT, Huang HL, Wang SP, Cheng FC, Wu J, Tsai MT (2014) A Comparison of Micro-CT and Dental CT in Assessing Cortical Bone Morphology and Trabecular Bone Microarchitecture. *PLoS One* 9: 107545
- Hsu WK, Mishra A, Rodeo SR, Fu F, Terry MA, Randelli P, Canale ST, Kelly FB (2013) Platelet-rich Plasma in Orthopaedic Applications: Evidence-based Recommendations for Treatment. *J Am Acad Orthop Surg* 21: 739-748.
- Jungbluth P, Wild M, Grassmann JP, Ar E, Sager M, Herten M, Jäger M, Becker J, Windolf J, Hakimi M (2010) Platelet-rich plasma on calcium phosphate granules promotes metaphyseal bone healing in minipigs. *J Orthop Res* 8: 1448-1455.
- Kamoda H, Yamashita M, Ishikawa T, Miyagi M, Arai G, Suzuki M, Eguchi Y, Orita S, Sakuma Y, Oikawa Y, Inoue G, Ozawa T, Toyone T, Wada Y, Takahashi K, Ohtori S (2012) Platelet-rich plasma combined with hydroxyapatite for lumbar interbody fusion promoted bone formation and decreased an inflammatory pain neuropeptide in rats. *Spine (Phila Pa 1976)* 37: 1727-1733.
- Kaushick BT, Jayakumar ND, Padmalatha O, Varghese S (2011) Treatment of human periodontal infrabony defects with hydroxyapatite + β tricalcium phosphate bone graft alone and in combination with platelet rich plasma: a randomized clinical trial. *Indian J Dent Res* 22: 505-510.
- Kim ES, Kim JJ, Park EJ (2010) Angiogenic factor-enriched

- platelet-rich plasma enhances in vivo bone formation around alloplastic graft material. *J Adv Prosthodont* 2: 7-13.
- Malhotra A, Pelletier MH, Yu Y, Walsh WR (2013) Can platelet-rich plasma (PRP) improve bone healing? A comparison between the theory and experimental outcomes. *Arch Orthop Trauma Surg* 133: 153-165.
- Okuda K, Tai H, Tanabe K, Suzuki H, Sato T, Kawase T, Saito Y, Wolff LF, Yoshixi H (2005) Platelet-rich plasma combined with a porous hydroxyapatite graft for the treatment of intrabony periodontal defects in humans: a comparative controlled clinical study. *J Periodontol* 76: 890-898.
- Oryan A, Meimandi Parizi A, Shafiei-Sarvestani Z, Bigham AS (2012) Effects of combined hydroxyapatite and human platelet rich plasma on bone healing in rabbit model: radiological, macroscopical, histopathological and biomechanical evaluation. *Cell Tissue Bank* 13: 639-651.
- Özdemir B, Kurtiş B, Tüter K, Sengüven B, Tokman B, Pinar-Özdemir S, Demirel I, Özcan G (2012) Double-application of platelet-rich plasma on bone healing in rabbits. *Med Oral Patol Oral Cir Bucal* 17: e171-e177.
- Özdemir B, Okte E (2012) Treatment of intrabony defects with beta-tricalciumphosphate alone and in combination with platelet-rich plasma. *J Biomed Mater Res B Appl Biomater* 100: 976-983.
- Piątkowski S, Kotwicki T (2004) Introduction to the pathophysiology of the musculoskeletal system. In: Marciniak W, Szulc A (eds) *Wiktora Dega Orthopedics and Rehabilitation*. PZWL Warsaw, pp 12-13.
- Plachokova AS, van den Dolder J, Stoelinga PJ, Jansen JA (2007) Early effect of platelet-rich plasma on bone healing in combination with an osteoconductive material in rat cranial defects. *Clin Oral Implants Res* 18: 244-251.
- Plachokova AS, van den Dolder J, Stoelinga PJ, Jansen JA (2006) The bone regenerative effect of platelet-rich plasma in combination with an osteoconductive material in rat cranial defects. *Clin Oral Implants Res* 17: 305-311.
- Rabillard M, Grand JG, Dalibert E, Fellah B, Gauthier O, Niebauer GW (2009) Effects of autologous platelet rich plasma gel and calcium phosphate biomaterials on bone healing in an ulnar osteotomy model in dogs. *Vet Comp Orthop Traumatol* 22: 460-466.
- Roffi A, Filardo G, Kon E, Marcacci M (2013) Does PRP enhance bone integration with grafts, graft substitutes, or implants? A systematic review. *BMC Musculoskelet Disord* 14: 330.
- Sawicki W (2008) Bone tissue. In: *Histology*. PZWL, Warsaw, pp 182-200.
- Skwarcz S, Bryzek I (2015) The use of plate-derived preparations (PRP) in the healing of deficits in bone tissue in the course of injuries and civilization diseases in orthopedics, traumatology and veterinary medicine. In: Spisacka S, Markert R (eds) *The impact of the disease, the level of health-related knowledge and education on the quality of life of patients*. Pope John Paul II State School of Higher Education in Biala Podlaska Publishing House, Biala Podlaska, pp 161-167.
- Suba Z, Takács D, Gyulai-Gaál S, Kovács K (2004) Facilitation of beta-tricalcium phosphate-induced alveolar bone regeneration by platelet-rich plasma in beagle dogs: a histologic and histomorphometric study. *Int J Oral Maxillofac Implants* 19: 832-838.
- Sulek K (2011) Structure of hemoglobin. Characteristics of blood and morphotic elements. In: Dmoszyńska A (ed) *Hematology*. Medical Tribiune Polska, Warsaw, pp. 28-32.
- Tamura K, Sato S, Kishida M, Asano S, Murai M, Ito K (2007) The use of porous beta-tricalcium phosphate blocks with platelet-rich plasma as an onlay bone graft biomaterial. *J Periodontol* 78: 315-321.
- Velich N, Kovács K, Huszár T, Semjén G, Reiczigel J, Szabó G, Suba Z (2004) The effect of platelet-rich plasma on new bone formation by augmentation with osseoconductive bone substitute material in beagle dogs. *Fogorv Sz* 97: 23-27.
- Williams RC, Cochran DL, Giannobile WV, Lynch SE (2005) Tissue engineering: what does it mean? Why is it important? *Compend Contin Educ Dent* 26: 54, 56, 58.